Online Data Supplements

Low-energy shockwave therapy improves the swine ischemic kidney microcirculation

Xin Zhang[1], James D. Krier[1], Carolina Amador Carrascal[3], James F. Greenleaf[3], Behzad Ebrahimi[1], Ahmad F. Hedayat[1], Stephen C. Textor[1], Amir Lerman[2], Lilach O. Lerman[1,2]

Affiliation:

[1]Division of Nephrology and Hypertension and the Departments of [2]Cardiology and [3]Physiology and Biomedical Engineering, Mayo Clinic, Rochester, MN, United States

Correspondence:

Lilach O. Lerman, MD, PhD, Division of Nephrology and Hypertension, Mayo Clinic, 200 First Street SW, Rochester, MN 55905.

Fax: (507)-266-9316 Phone: (507)-266-9376 Email : lerman.lilach@mayo.edu

Supplemental Tables

Table S1. Acute kidney injury markers before and after single session SW treatment in 2 normal pigs (mean±SEM).

Characteristics	Before SW	After SW
Hematuria	-	-
Urine protein (mg/dl)	32.1±3.2	31.0±6.5
NGAL (ng/ml)		
Urine	4.1±0.7	3.5±1.0
Renal vein (stenotic, ng/ml)	106.4±10.5	102.0±7.8

NGAL: neutrophil gelatinase-associated lipocalin

Supplemental Figure 1

A

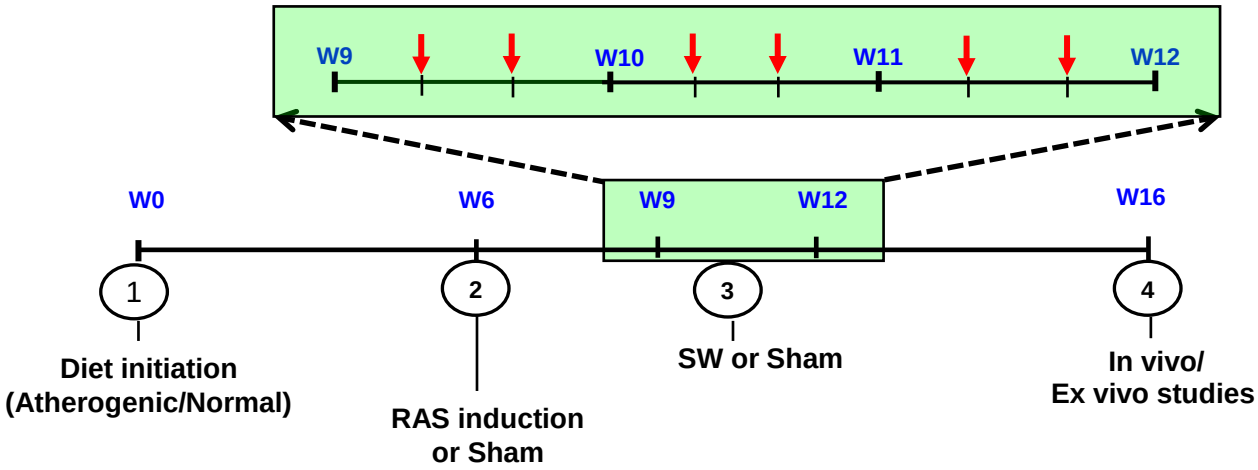

B

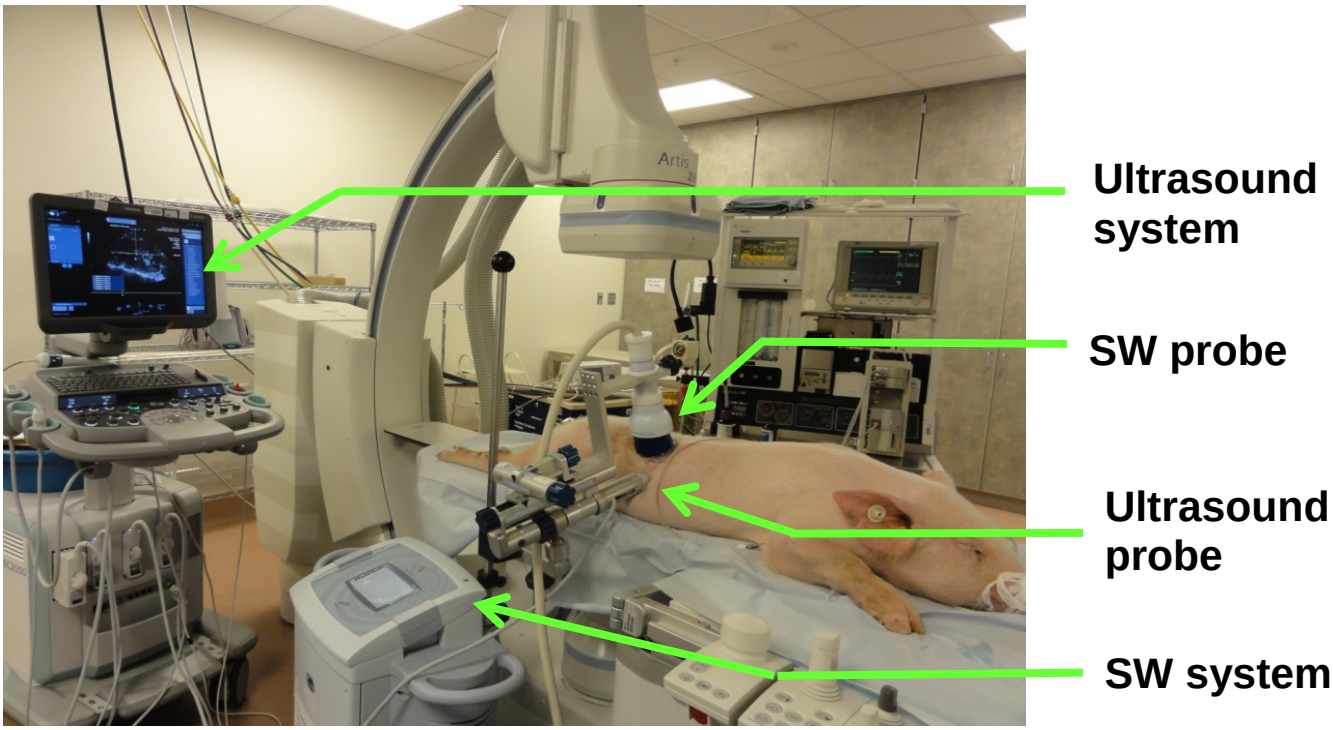

C

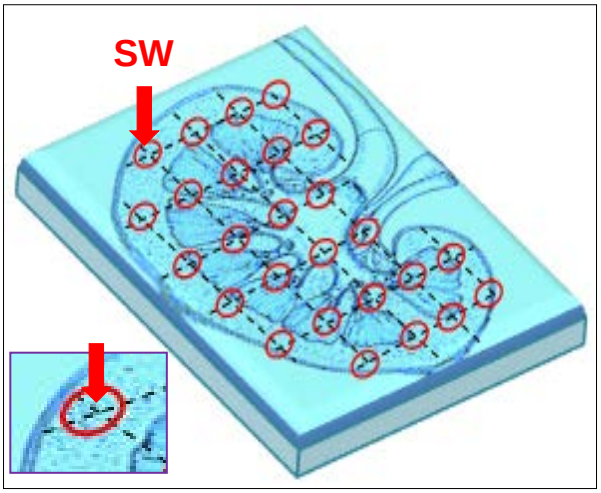

D

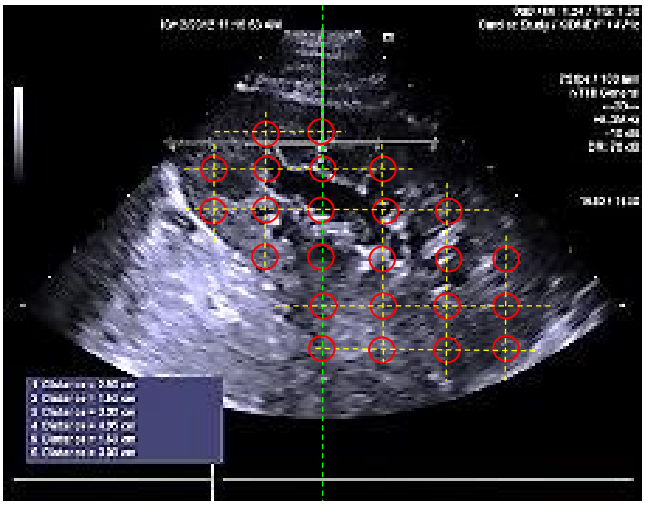

Supplemental Figure 2

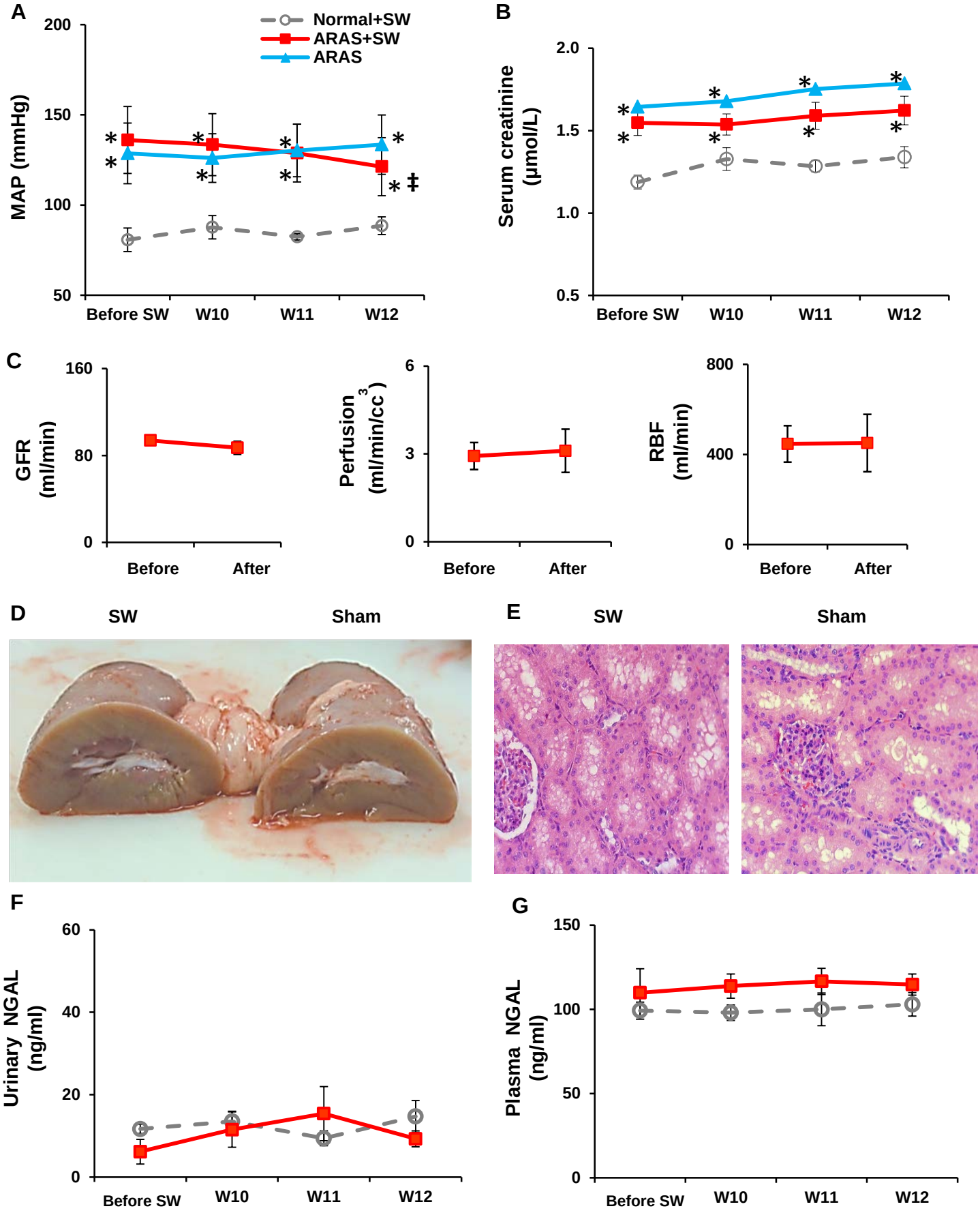

Supplemental Figure 3

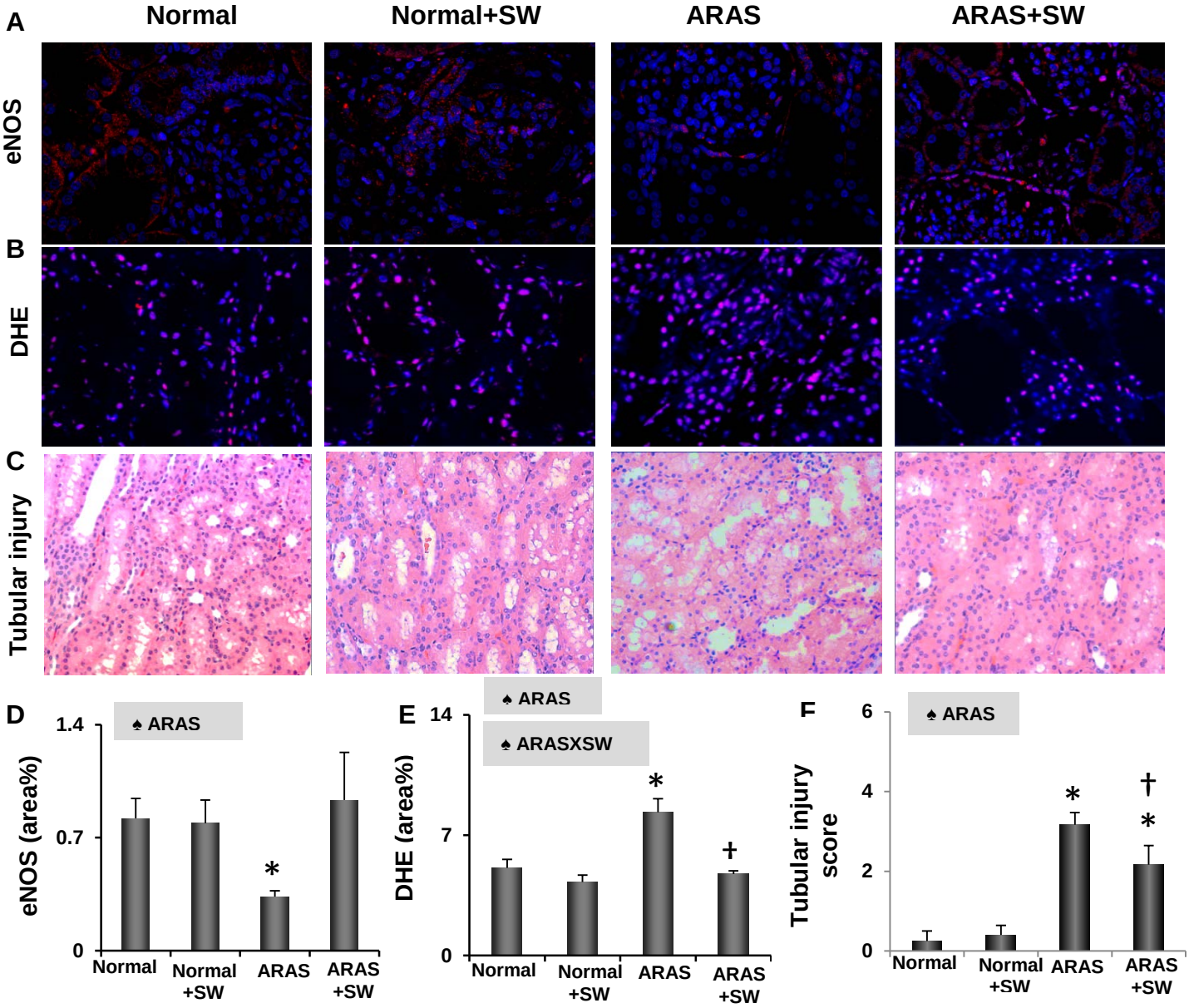

Supplementary Figure 1. A: Schematic of a 16-wk experimental protocol, with 6 shockwave (SW) sessions delivered over a 3-week regimen (weeks 9, 10 and 11; each SW session indicated by a red arrow). B: Illustration of a SW experiment set-up. Green arrows indicate the SW and ultrasound probes and systems, which are coordinated to localize delivery of the SW. C-D: Ultrasound image and illustration of SW treatment zones along the short axis of the kidney.

Supplementary Figure 2. A,B: Over the 3-week course of treatment (week 10 through week 12), SW decreased MAP in atherosclerotic renal artery stenosis (ARAS). Serum creatinine remained unchanged in ARAS groups; C-E: Glomerular filtration rate (GFR), renal perfusion, and renal blood flow (RBF), as well as gross and microscopic renal images obtained immediately after a single session of SW in 2 normal animals. Single session SW caused no noticeable damage to renal function or structure. F,G: Urine and renal vein plasma neutrophil gelatinase-associated lipocalin (NGAL) from SW treated normal and ARAS pigs did not change during 3-week SW regimen. *$p<0.05$ vs. Normal+SW, ‡: $p<0.05$ vs. Before SW.

Supplementary Figure 3. A,D: Representative images and quantification of endothelial nitric oxide synthase (eNOS, red) immunoreactivity. SW improved eNOS expression in the ARAS kidney. B,E: SW alleviated renal oxidative stress increased by ARAS, as indicated by dihydroethidium (DHE). C,F: Representative H&E images for tubular injury score and quantification. SW alleviated tubular injury in ARAS. ♠ARAS: significant effect of ARAS; ♠ARASxSW: significant interaction of ARAS and SW (Two-way ANOVA).*$p<0.05$ vs. Normal, †$p<0.05$ vs. ARAS.

Supplemental Figure 4

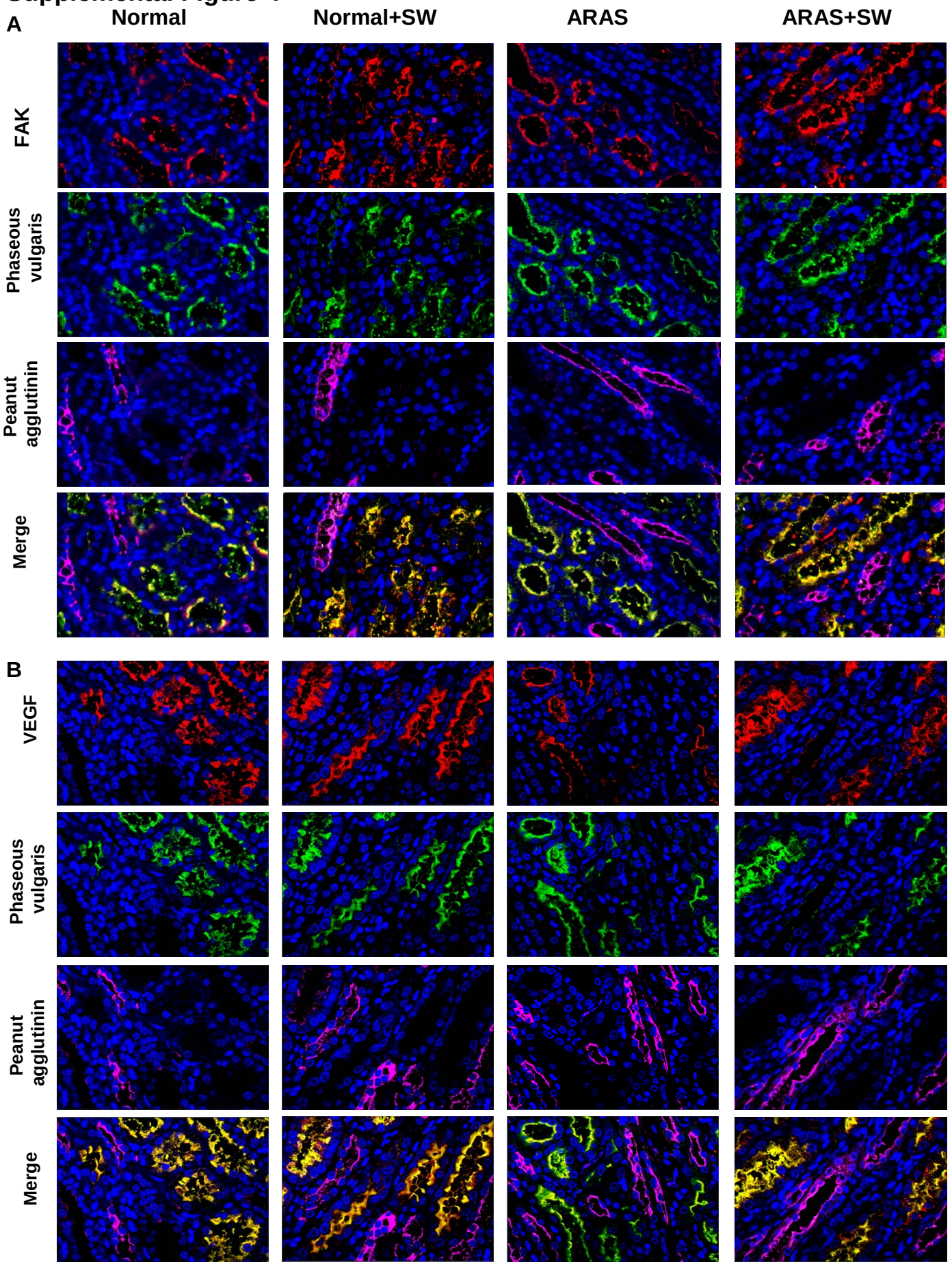

Supplemental Figure 5

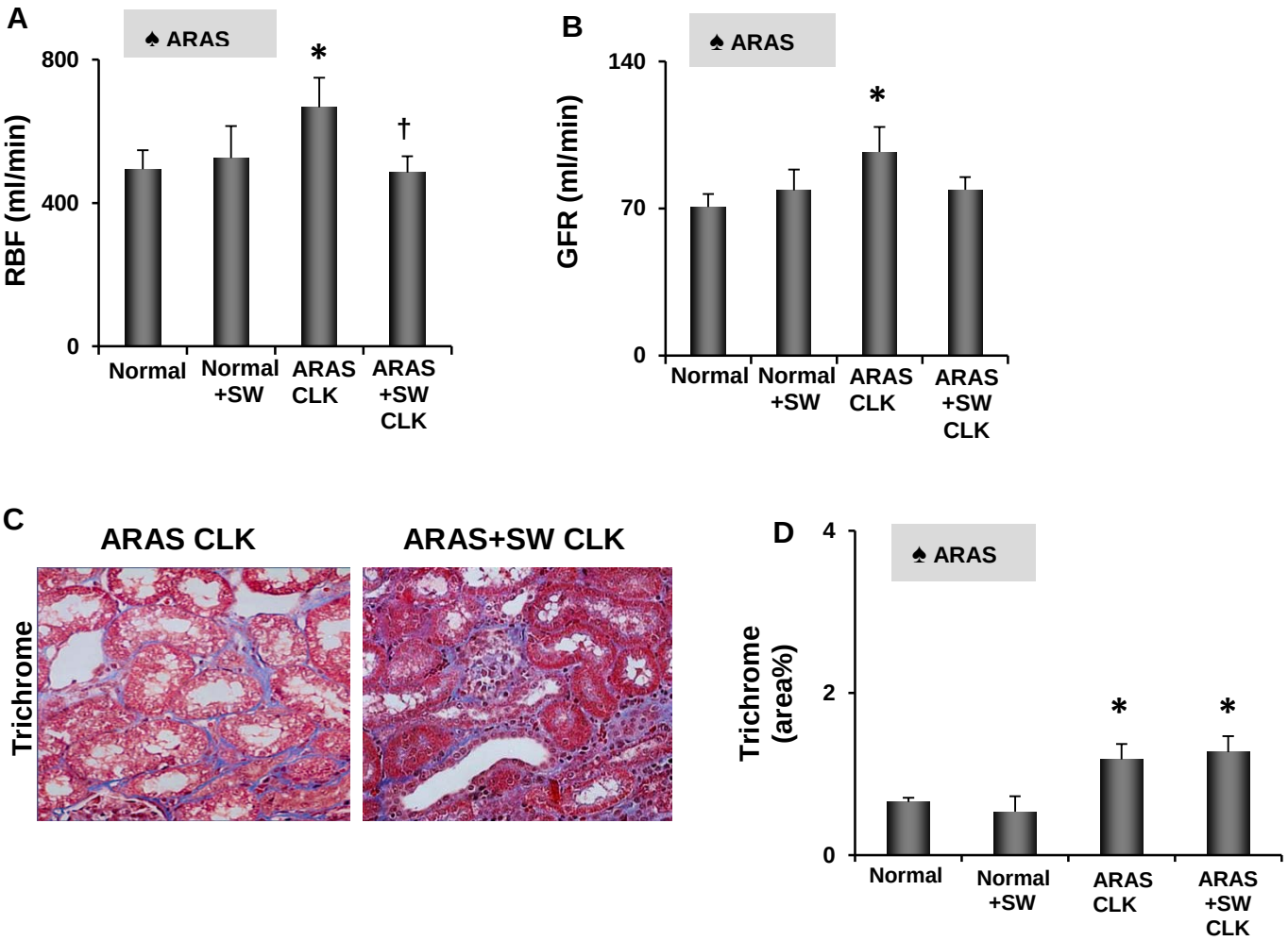

Supplementary Figure 4. A,B: Representative images of localization of focal adhesion kinase (FAK) and *vascular endothelial growth factor* (VEGF) staining (both red) with the proximal tubular marker phaseous vulgaris agglutinin (green, co-localized yellow) and distal tubular marker peanut agglutinin (pink), respectively. Mechanotransducer and angiogenic factor selectively expressed in proximal tubular cells.

Supplementary Figure 5. A,B: Renal blood flow (RBF) and glomerular filtration rate (GFR) were increased in the contralateral kidney (CLK) of ARAS, but not ARAS+SW. C,D: Representative images of trichrome in the CLK of ARAS and ARAS+SW and quantification. ♠ARAS: significant effect of ARAS (Two-way ANOVA). *$p<0.05$ vs. Normal, †$p<0.05$ vs. ARAS.

Supplemental Figure 6

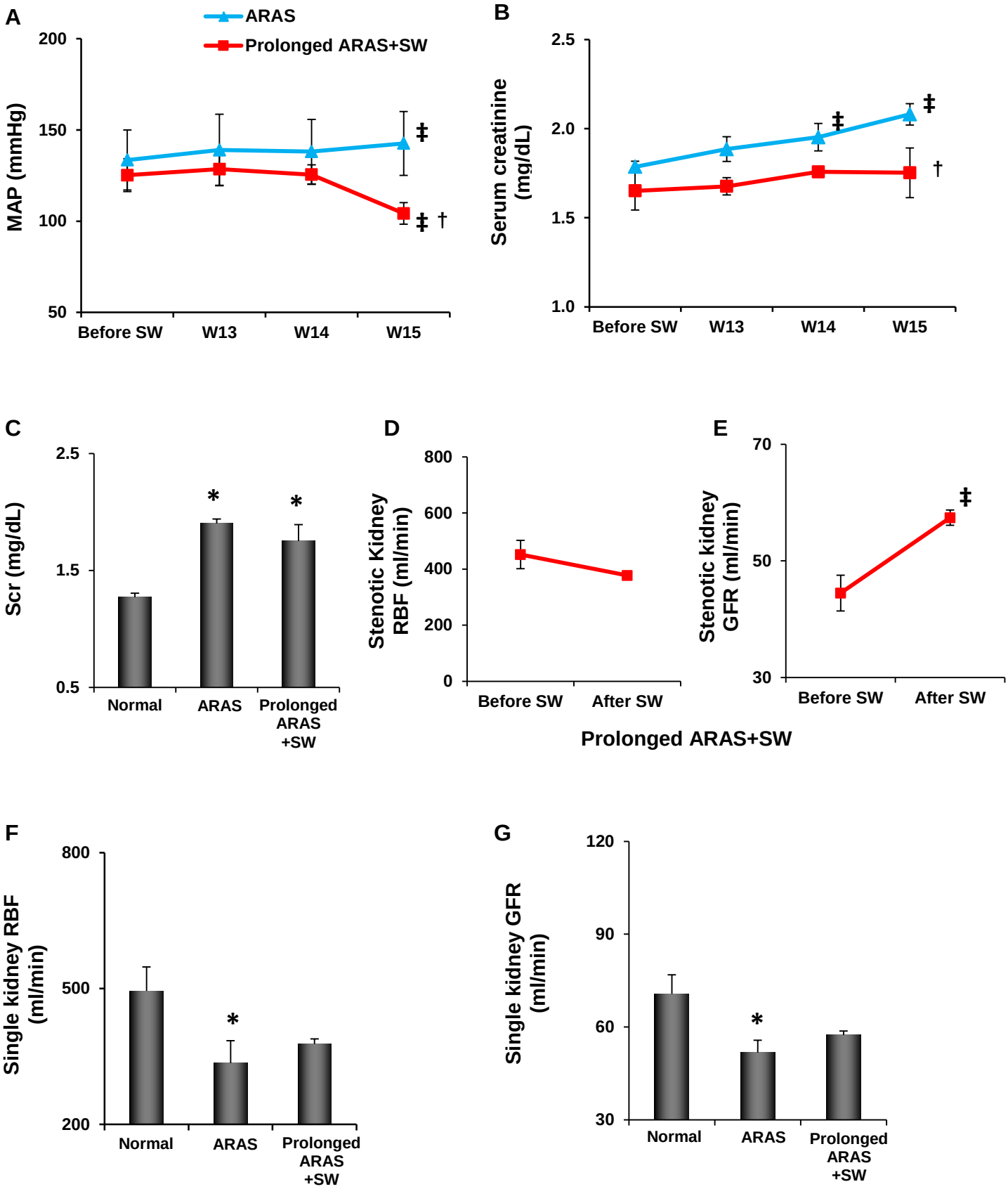

Supplemental Figure 7

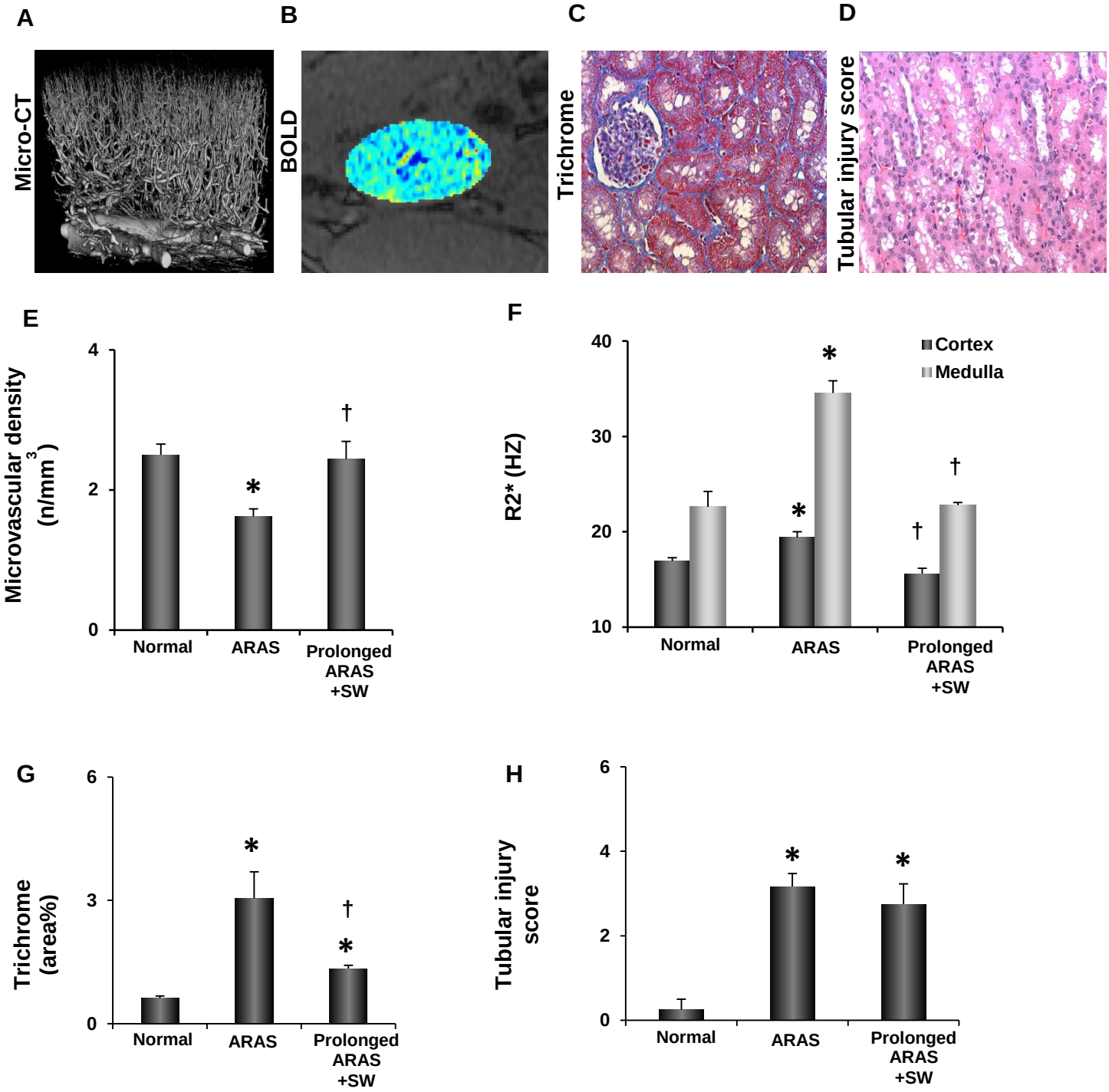

Supplementary Figure 6. A,B: SW decreased the mean arterial pressure (MAP) and stabilized serum creatinine (Scr) in Prolonged ARAS pigs, whereas in untreated ARAS both MAP and Scr increased over the same time period. C: Scr in Prolonged ARAS+SW at 16 weeks did not differ from ARAS or Normal. D,E: SW did not change renal blood flow (RBF), but improved stenotic kidney glomerular filtration rate (GFR) in Prolonged ARAS. F,G: Stenotic kidney RBF and GFR in Prolonged ARAS did not differ from ARAS or Normal kidneys. *p<0.05 vs. Normal, †p<0.05 vs. ARAS. ‡: p<0.05 vs. Before SW.

Supplementary Figure 7. A-D: Representative images of micro-computed tomography and blood-oxygen-level-dependent magnetic resonance imaging, trichrome and tubular injury score and their quantifications (E-H) in Prolonged ARAS. *p<0.05 vs. Normal, †p<0.05 vs. ARAS.