

FIGURE LEGEND

Supplemental figures

Supplemental Figure 1. Virtual plane and point cloud in 3D digital model of the foot. Front view.

Supplemental Figure 2. Resection-positioning guide with four cannulated cylinders attached to a template of the lateral aspect of the hindfoot.

Supplemental Figure 3. 3D resection-positioning guide placed over the exposed rim of bone using the anatomic references (it can only fit on the specific patient in the predefined position)

Supplemental Figure 4. The plane defined by the K-wires is used to align an oscillating saw and perform the main resection cut,.

A. Lateral view.

B. Front view.

Supplemental Figure 5. Main resection cut using the plane defined by the K-wires

Supplemental Figure 6. The osteotomy was finished using an osteotome.

Supplemental Figure 7. Main resection cut finished using an osteotome.

Supplemental Figure 8. X ray showing stabilization using an ankle fusion plate.

Supplemental Figure 9. Rearthrodesis stabilization using an ankle fusion plate.

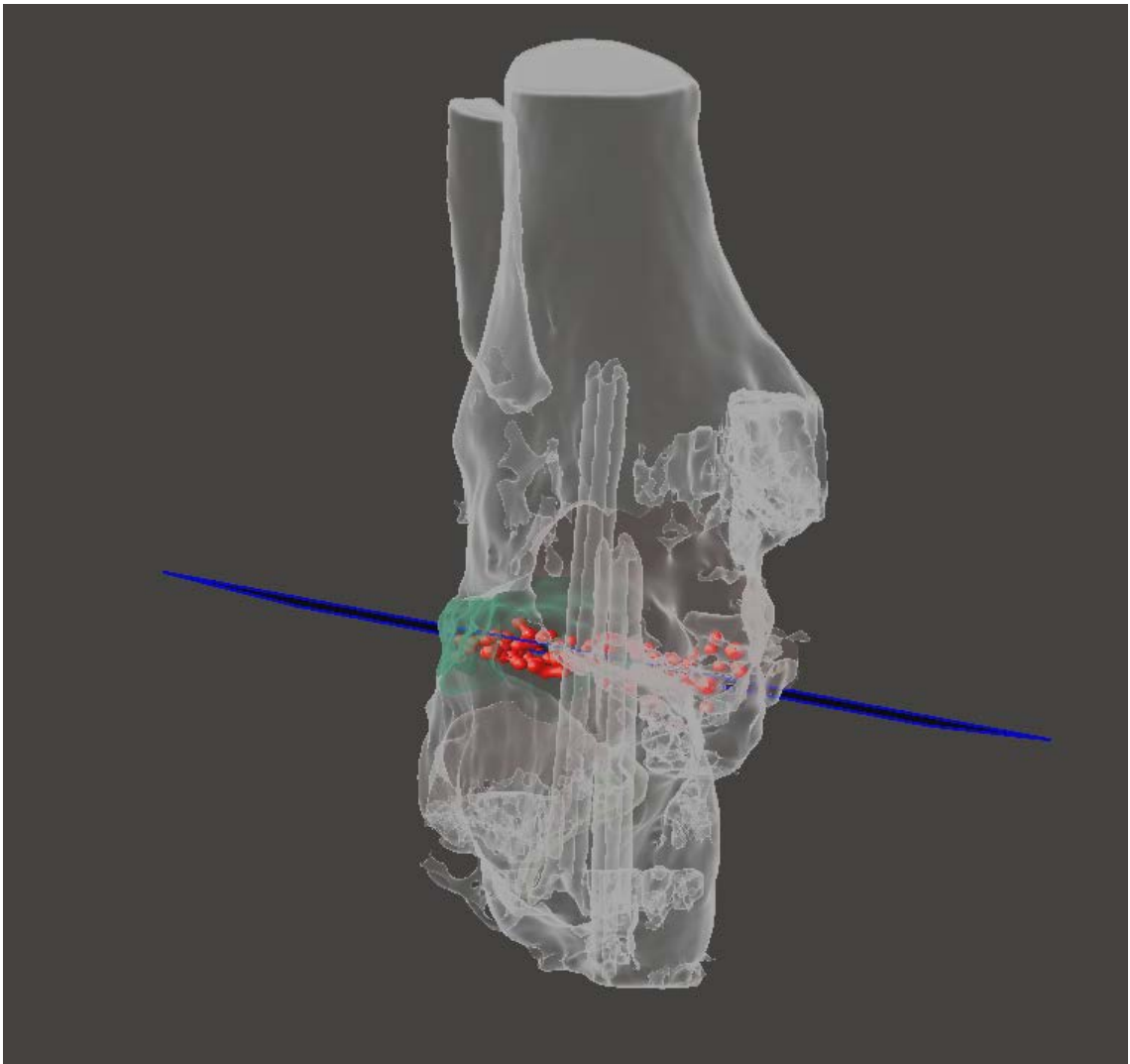
Supplemental Figure 10. Ankle arthrodesis: radiological control

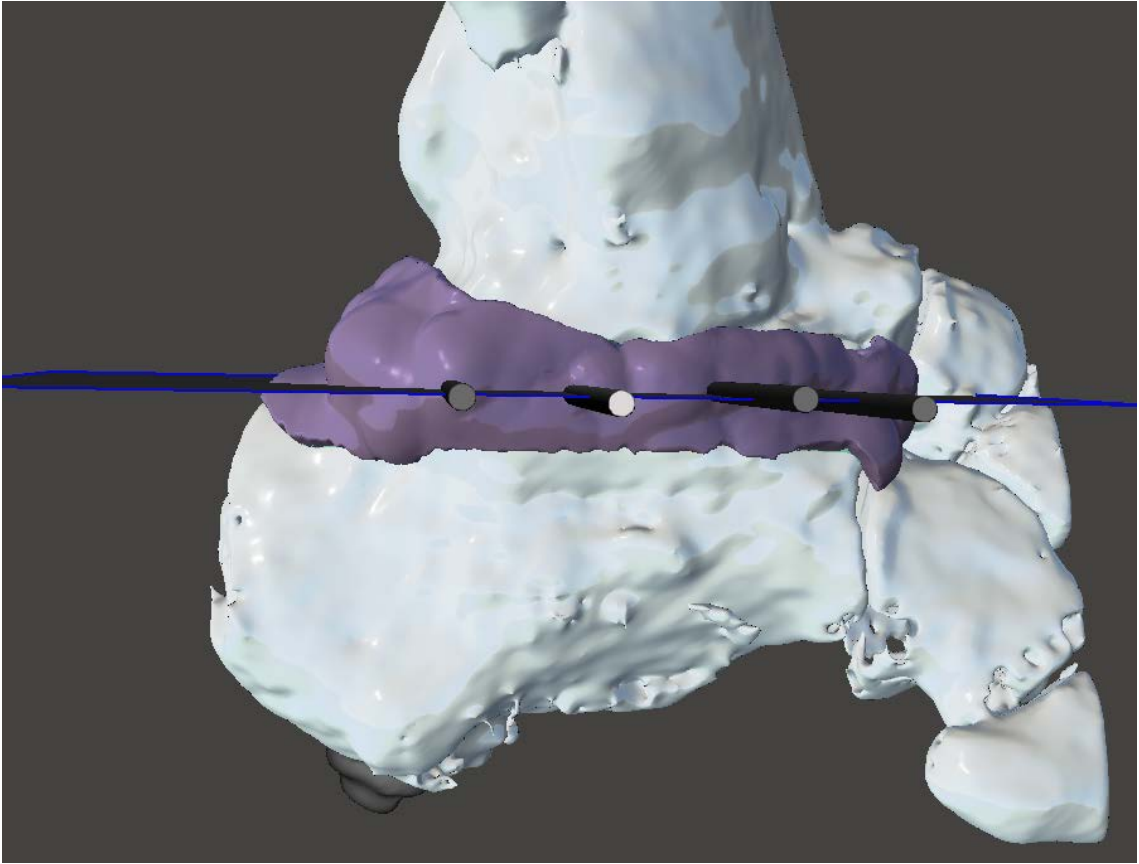
A. Preoperative

B. Postoperative

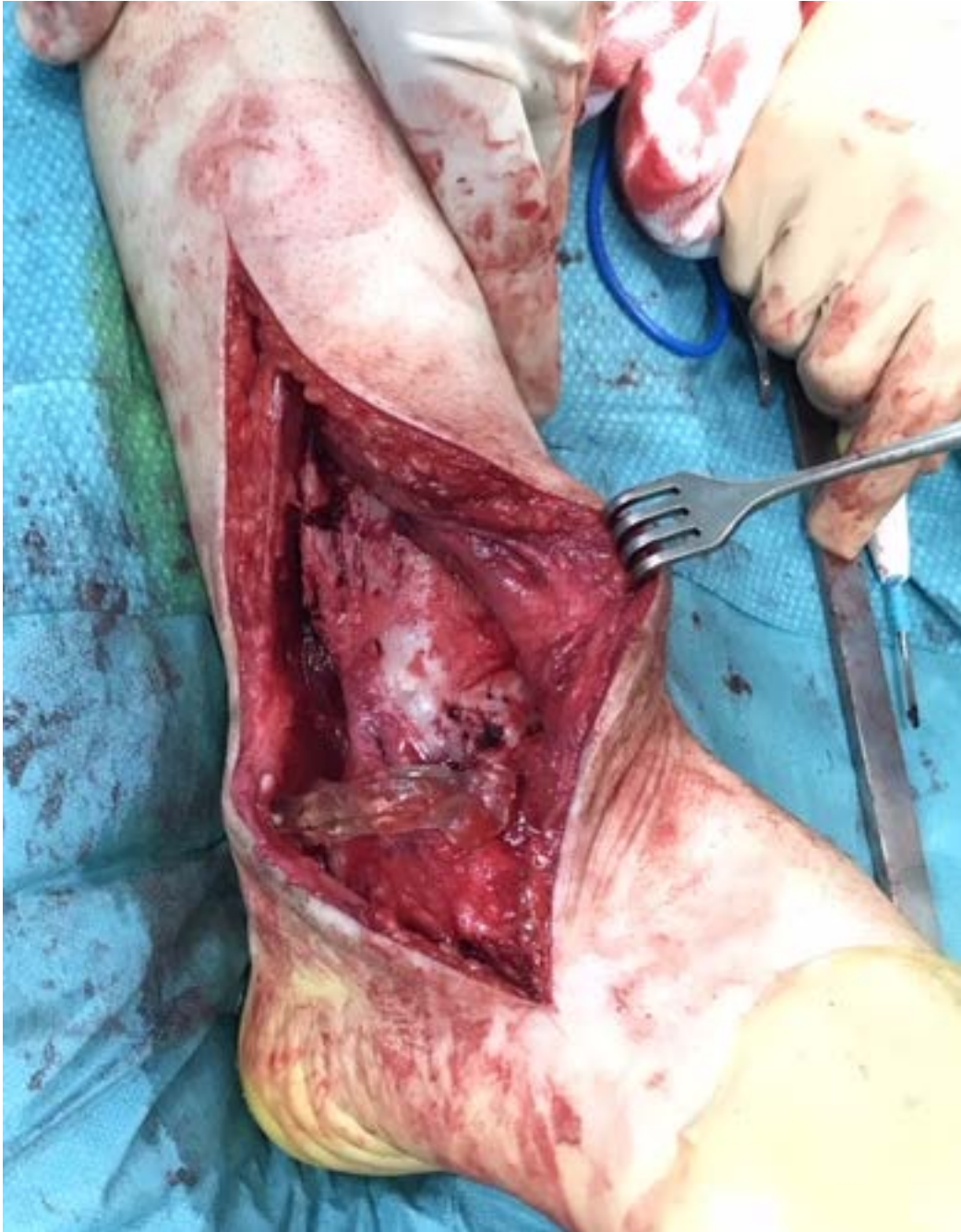23

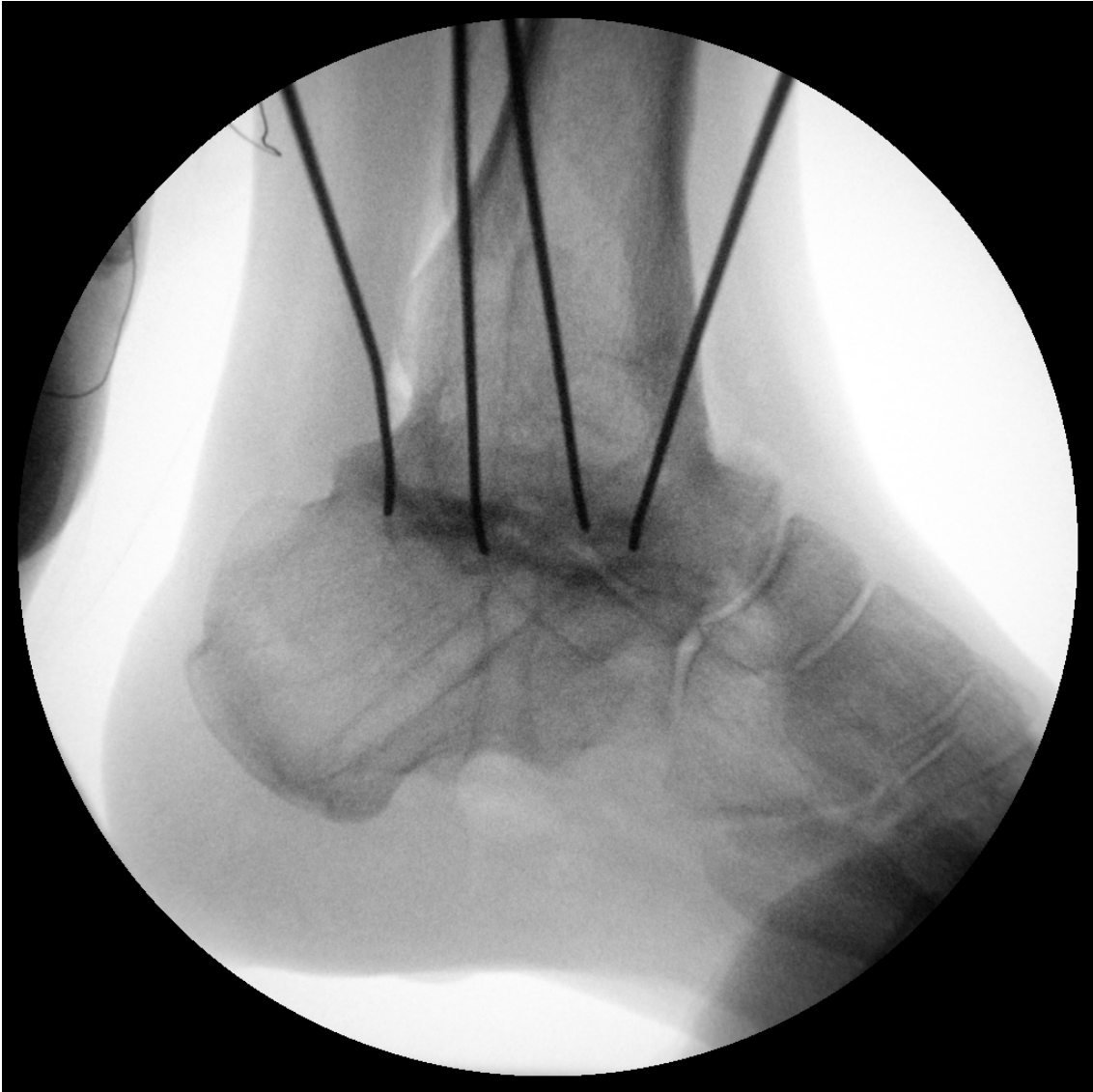24

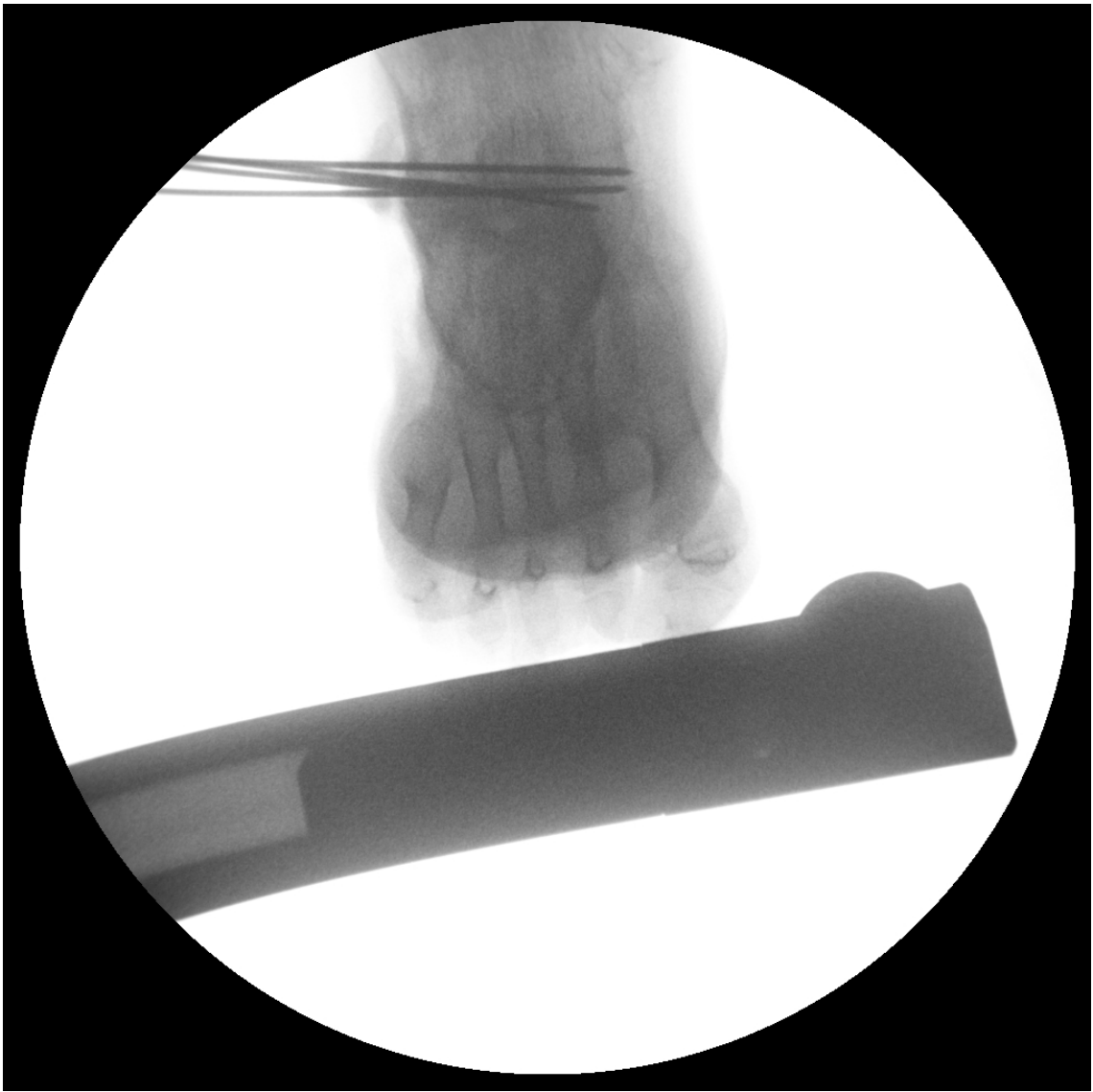

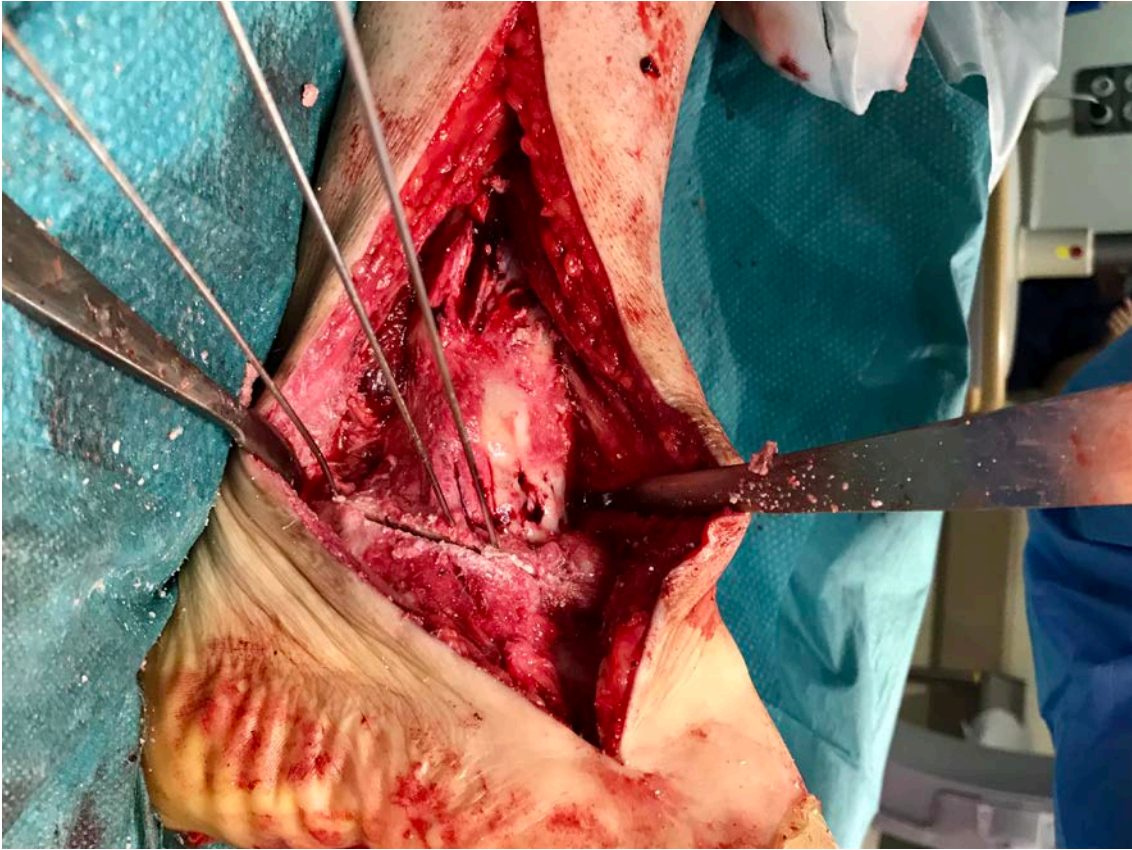


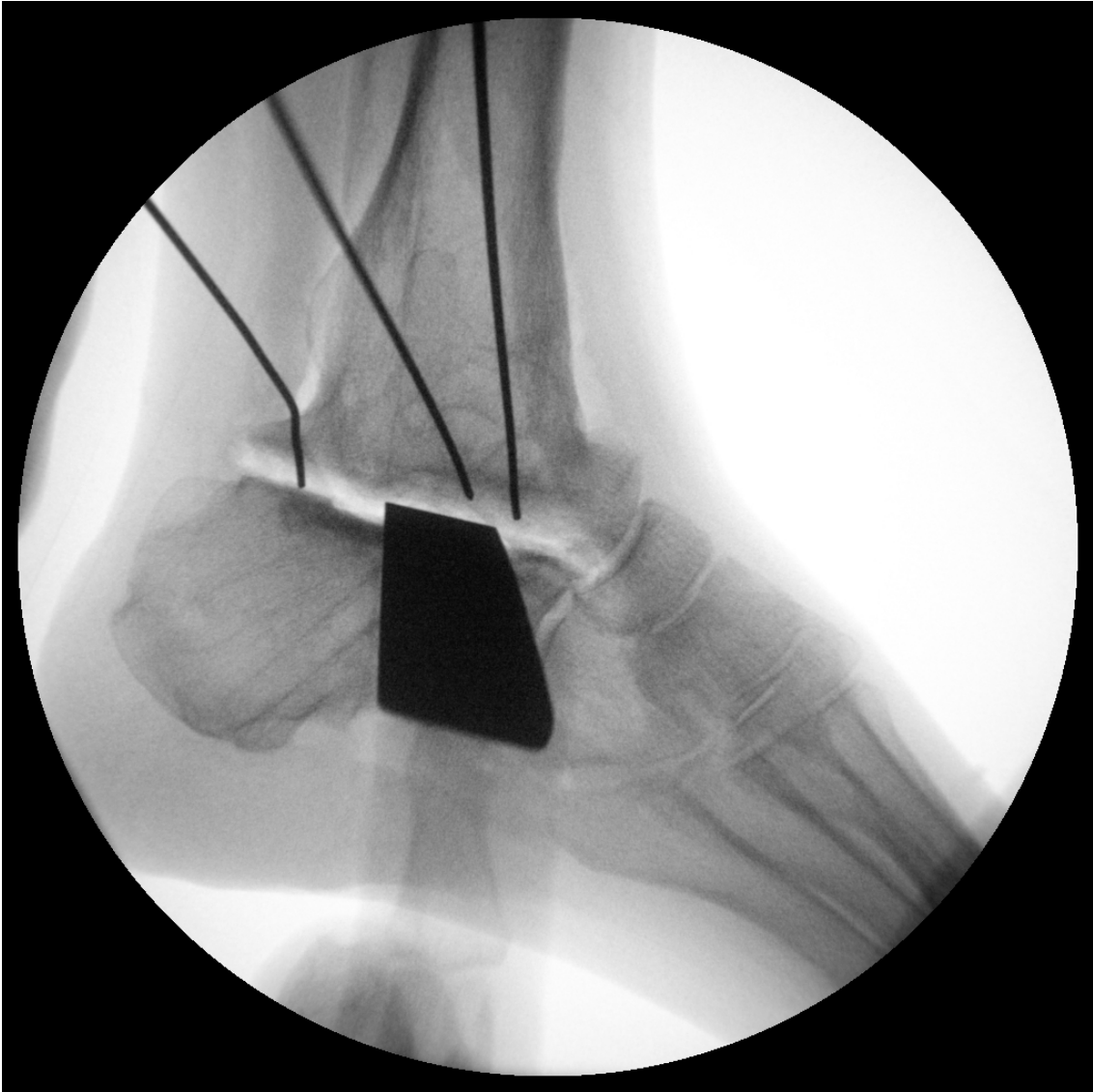26
27

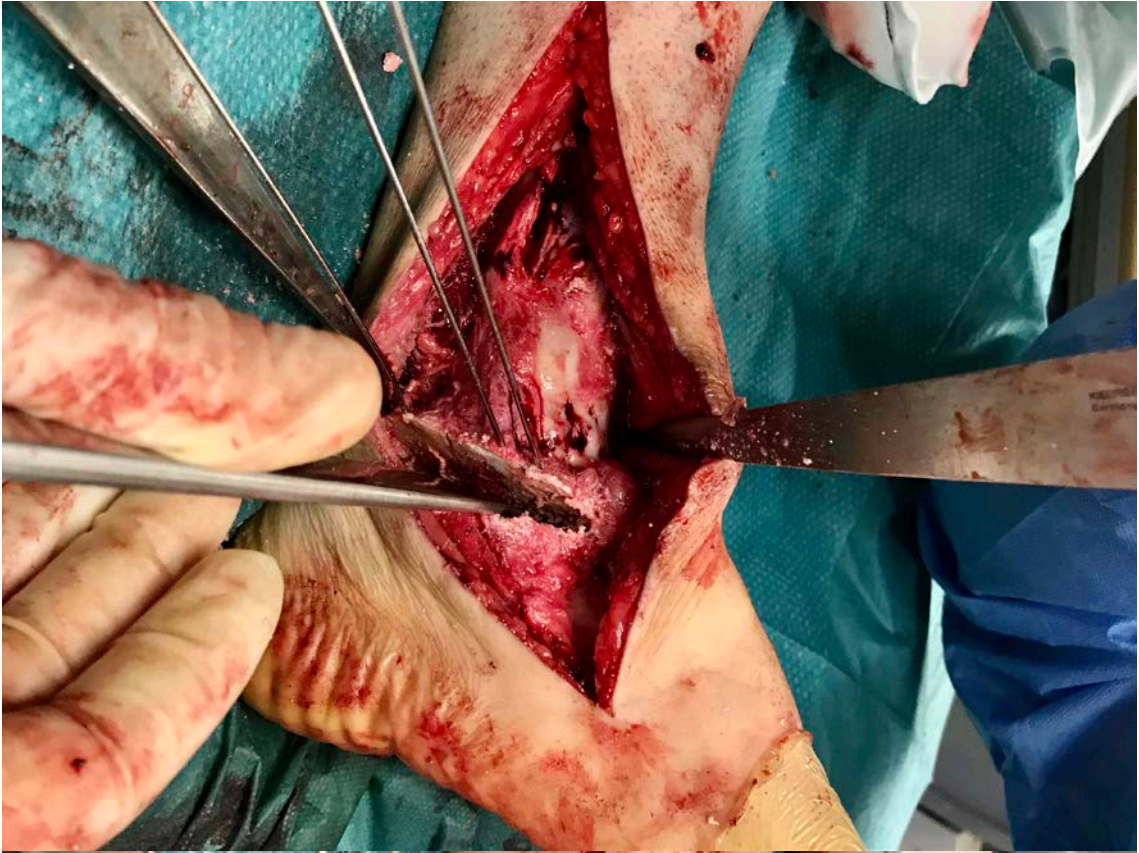




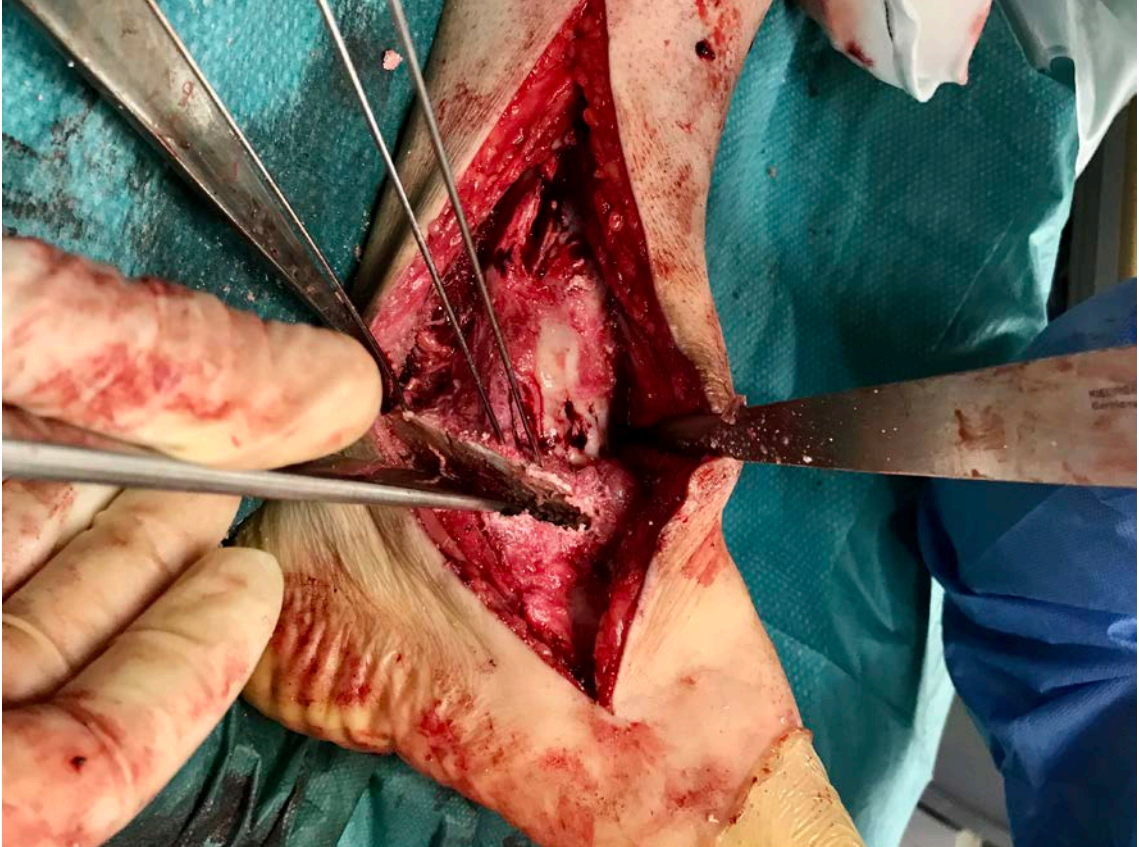




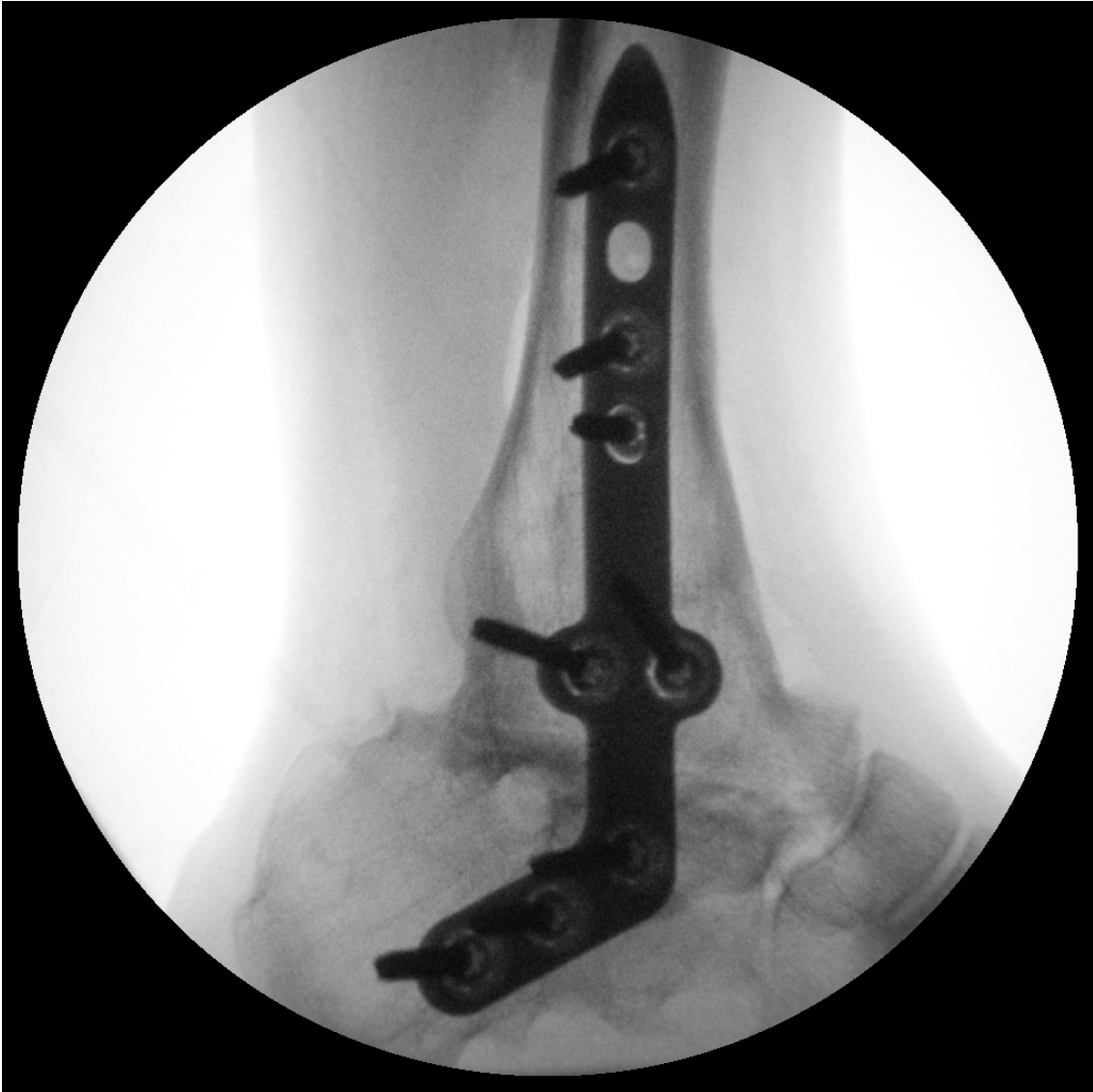

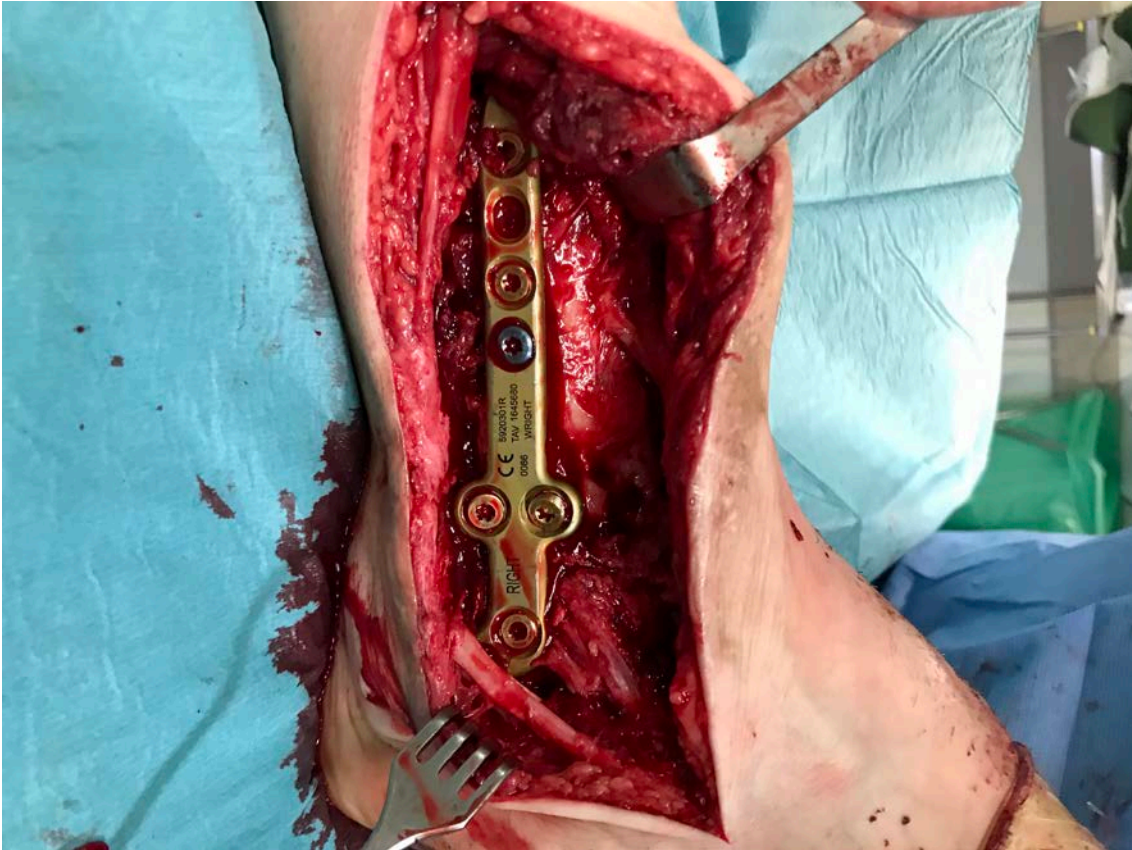


33

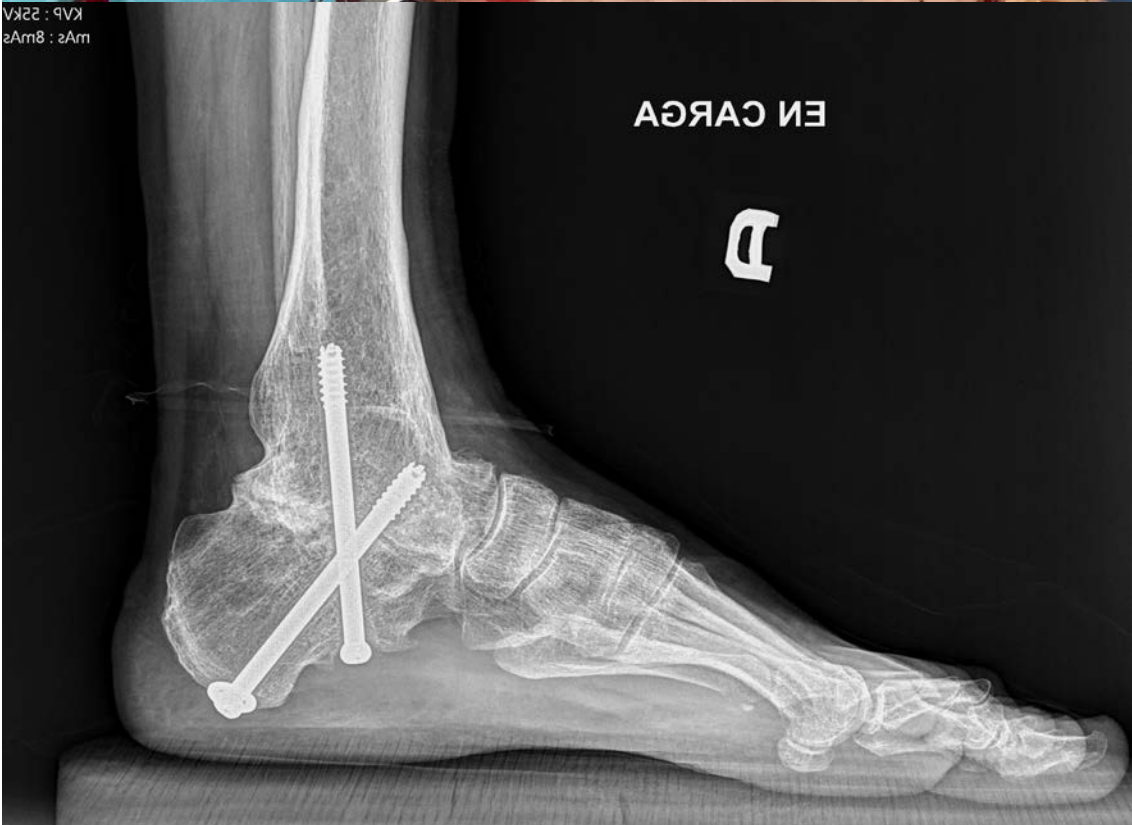

34





36



37

