

Case Reports

Case 1.

An 18 year old woman complained of headaches and diplopia. She had childhood amblyopia in the right eye owing to asymmetric myopia and esotropia.

She weighed 355 lbs and stood 5' 9." Best-corrected visual acuities were finger counting OD and 20/30 OS. Refraction was $-12.50+3.75 \times 89$ in the right eye and $-3.25+3.75 \times 91$ in the left eye. Pupils reacted normally to light without afferent pupil defect. Ocular ductions were full in both eyes and there was a comitant esotropia of 30 prism-diopters. Ophthalmoscopy showed staphylomatous dysplasia of the posterior segment in the right eye and mild disc margin elevation in the left eye (Fig 1). The Humphrey visual field in the left eye demonstrated a mean deviation of -8.00 dB with nasal field loss.

Brain MRI was normal. A fluoroscopically-guided LP showed an opening pressure of 48 cm H₂O. She was treated with acetazolamide 2 gm/day. One month later, she complained of worsening headache. Visual acuity OS had fallen to finger counting. Yet her visual field in that eye showed an improvement to a mean deviation of -4 dB. Optic discs appeared unchanged. The conflicting visual function information suggested that the data were unreliable. She was maintained on acetazolamide 2 gm/day.

Three months later she complained of acute visual loss in the left eye. Visual acuity was now hand movements in that eye. The appearance of the optic discs was unchanged. ICP monitoring showed a range of 2 to 15 cm H₂O with an average of 7 cm H₂O. The following day she reported marked improvement in vision. Visual acuity in the left eye had returned to 20/30 and the Humphrey visual field demonstrated a mean deviation of -4 dB. She was placed on standard analgesics for headache. Follow-up examinations over the next 7 years disclosed no change in visual acuity, visual fields, or optic disc appearance.

Summary: ICP monitoring revealed normal ICP in a woman with a history of elevated ICP on LP in the past. She had complained of acute visual loss in an eye with questionable optic disc elevation. The day after the normal ICP monitoring, vision returned to normal in the newly symptomatic eye.

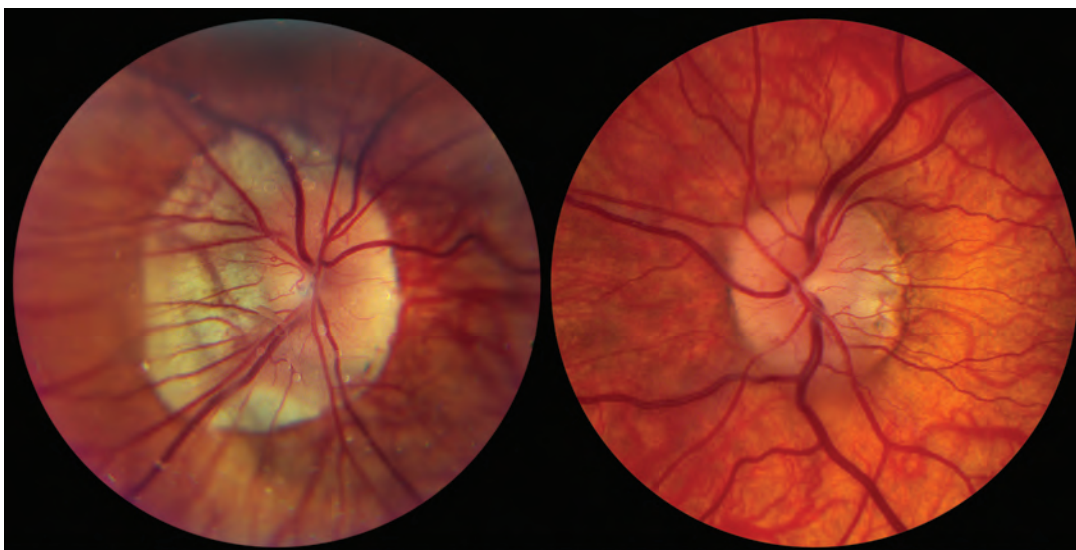


Figure 1. Case 1. Staphylomatous dysplasia of the posterior segment OD and mild disc margin elevation OS.

Case 2.

A 46-year-old man complained of frequent episodes of transient binocular visual loss precipitated by body movement but not by assuming an upright posture. An ophthalmologist had found “hemorrhage in both eyes.” Brain MRI was normal, but LP showed an ICP “three times normal.” Records could not be located. The finding of elevated ICP led to prompt consecutive optic nerve sheath fenestrations (ONSFs) in both eyes. Vision remained subnormal post-operatively but transient visual obscurations subsided. He denied a major recent increase in weight.

Best-corrected visual acuities were 20/20 in both eyes with normal pupil function. Humphrey visual fields showed mean deviations of -15 dB OD and -12 dB OS with nerve fiber bundle defects OU. Ophthalmoscopy disclosed a mixture of optic disc pallor and swelling OD and chronic optic disc swelling OS (Fig 2). A fluoroscopically-guided LP revealed an ICP of 32 cm H₂O. ICP monitoring showed ICPs ranging from 3 to 19.5 cm H₂O with an average of 13.6 cm H₂O. The patient was not treated. One year later, there was no change in his ophthalmic status.

Summary: ICP monitoring revealed normal ICP in a patient with elevated ICP on several LPs and confusing clinical features.

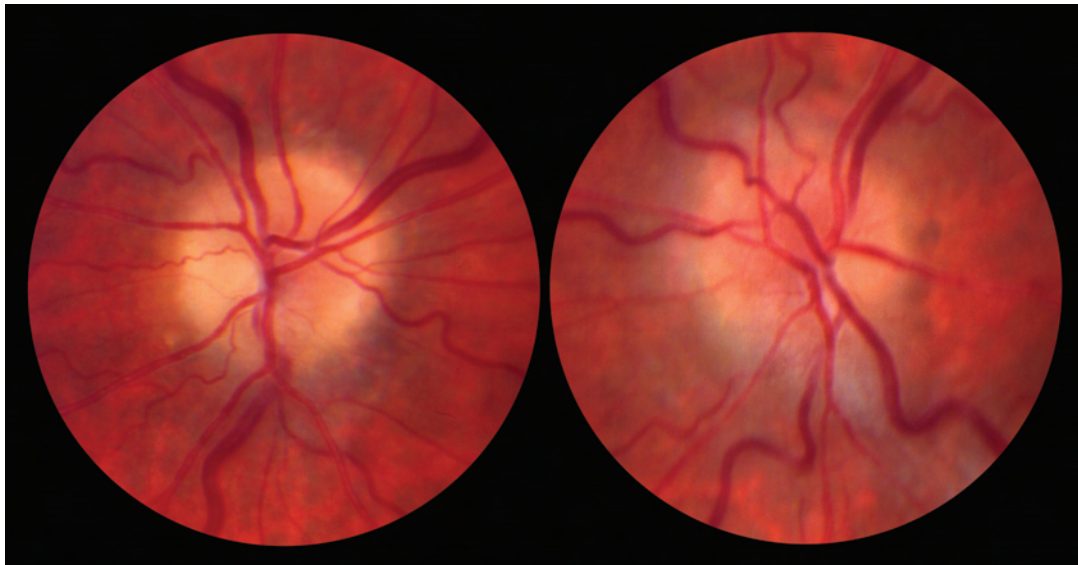


Figure 2. Case 2. Optic disc pallor and swelling OD and chronic optic disc swelling OS.

Case 3.

A 23-year-old woman developed neck and head pain followed by blurred and transient obscurations of vision in both eyes. Visual acuity was measured elsewhere at 20/50 in the right eye and 20/20 in the left eye with a right afferent pupil defect. Marked acute swelling of the optic disc in the right eye and moderate swelling of the optic disc in the left eye were described in examinations performed elsewhere. The visual field in the right eye showed only a 5-degree island at 2 degrees temporally with the largest Goldmann test object. In the left eye, she had a nearly normal visual field.

Brain MRI was normal. She underwent urgent ONSF in the right eye elsewhere. The headaches and transient obscurations of vision resolved post-operatively. Optic disc edema was replaced with pallor. In the next few months, she complained of visual loss on the unoperated left eye. LP performed elsewhere showed an opening pressure of 38 cm H₂O with a normal formula.

Neuro-ophthalmologic examination disclosed best-corrected visual acuities of hand movements in the right eye and 20/20 in the left eye. A Humphrey visual field showed a mean deviation of -5 dB in the left eye. A large right afferent pupil defect was present. Marked optic disc pallor was present in the right eye and mild optic disc pallor in the left eye (Fig 3). ICP monitoring ranged from 12 to 20 cm H₂O with an average of 18.2 cm H₂O. No treatment occurred and over the next 18 months, her headaches abated and visual function remained stable.

Summary: ICP monitoring disclosed normal ICP in a woman with an elevated LP opening pressure and a history consistent with IIH who had undergone ONSF in one eye which confounded interpretation of the optic disc. Without further treatment for IIH, headaches abated and visual function remained stable during an 18-month follow-up period.

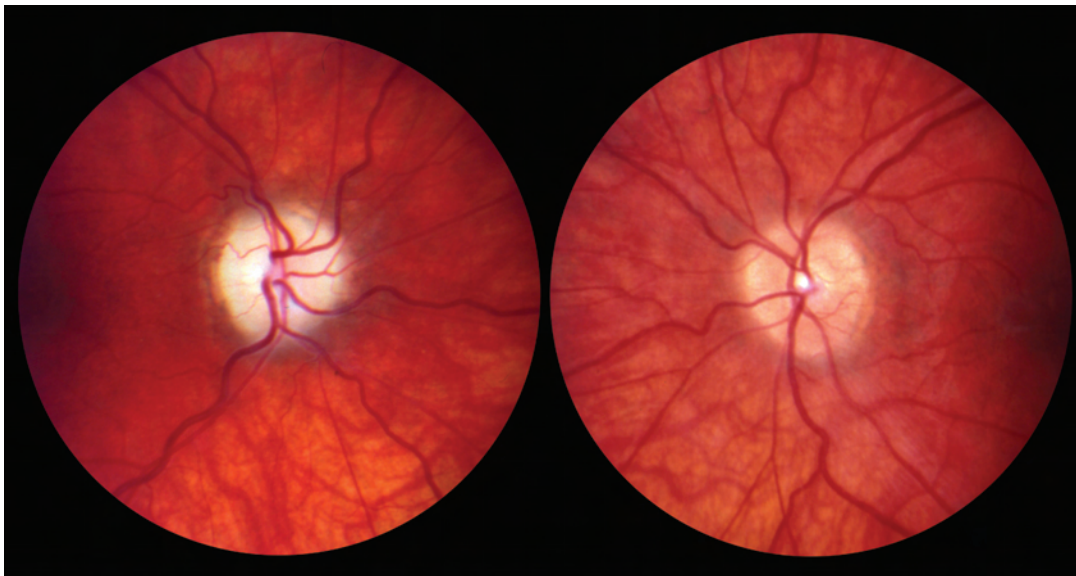


Figure 3. Case 3. Marked optic disc pallor OD and mild optic disc pallor OS.

Case 4.

A 25 year old woman complained of worsening headache and episodic cloudy and sparkly vision in the right eye for several months. Two years earlier, she had complained of limb weakness and was diagnosed as having a mitochondrial myopathy by muscle biopsy. Medications included carnitine, co-enzyme Q, and vitamins C, B-50, and E.

Visual acuity was 20/20 in both eyes with -7.00 spherical equivalent. Pupils were normal. Humphrey visual fields showed mean deviations of -5 dB in the right eye and -2 dB in the left eye. Ophthalmoscopy disclosed mild optic disc elevation in both eyes (Fig 4). Neurological examination was otherwise normal. Brain MRI and MRV were normal. LP showed an opening pressure of 31 cm H_2O with a normal CSF formula. She was treated with acetazolamide 1500 mg/day. Over the ensuing weeks, she noted improvement in vision but reported more generalized weakness. Acetazolamide was tapered off. Her weakness resolved, but her visual symptoms and headaches returned. There was a slight worsening in the optic disc elevation.

ICP monitoring revealed a range of 7 to 30 cm H_2O with an average of 27 cm H_2O . She underwent ventriculo-peritoneal (VP) shunt placement the following day. Two years later, optic discs showed less edema and visual fields showed mean deviations of -3 dB in the right eye and -2 dB in the left eye.

Summary: ICP monitoring revealed an elevated ICP and sustained a diagnosis of IIH in a woman with slightly blurred optic disc margins and intolerance to acetazolamide, justifying placement of a VP shunt. Two years later, the optic disc edema had lessened and the visual field in the right eye had improved. Approximately 2.5 years after shunt placement, however, she developed meningitis and died.

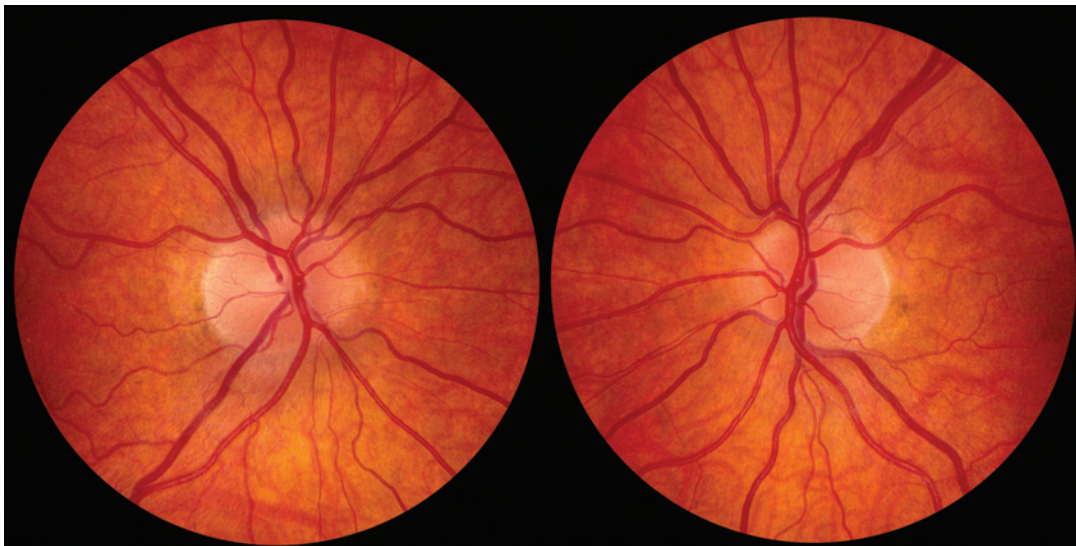


Figure 4. Case 4. Mild optic disc elevation OU.

Case 5.

A 24-year old woman developed headache and bilateral visual loss over several months. Ophthalmologic examination disclosed finger counting vision in the right eye and 20/30 in the left eye with bilateral optic disc edema.

Brain MRI was normal. LP showed an opening pressure of 47 cm H₂O with a normal formula. She was treated with acetazolamide 1 gm/day. Headaches abated but vision remained stable. One year later, visual acuities were unchanged and a Humphrey visual field test showed a mean deviation of -28 dB in the left eye. Both optic discs were pale with gliosis (Fig 5). ICP monitoring showed ICPs ranging between 2 and 19 cm H₂O. Acetazolamide was eventually discontinued. Five years later, visual function was unchanged.

Summary: ICP monitoring revealed a normal ICP in a patient with a markedly elevated LP opening pressure. Both optic discs were pale from longstanding IIH. The normal ICP monitoring allowed the presumption that the IIH was “burned out” and that the acetazolamide could be safely discontinued. Five years later, visual function was unchanged.

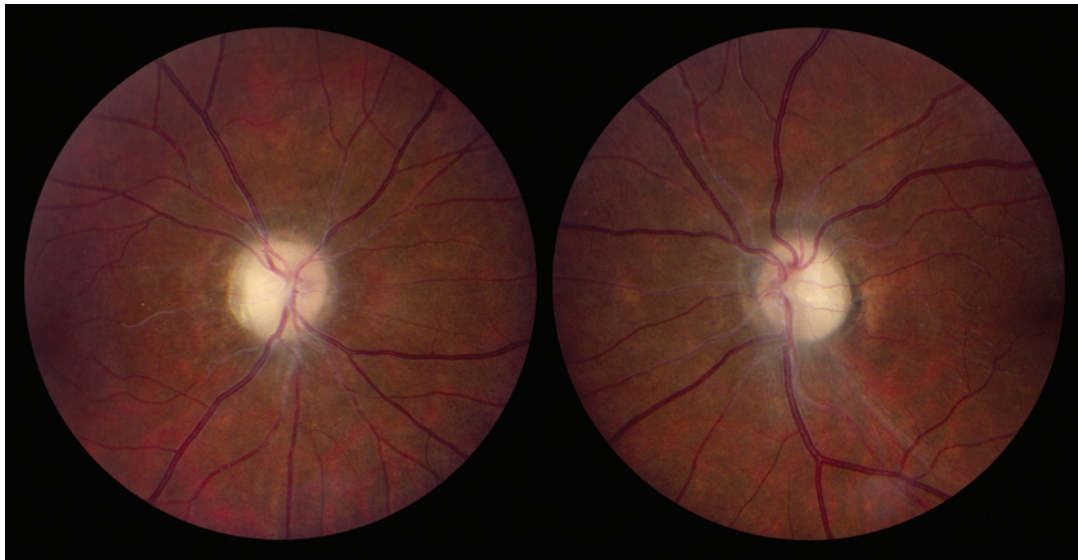


Figure 5. Case 5. Optic disc pallor with gliosis OU.

Case 6.

A 7-year-old boy developed severe episodic headaches lasting for one to three days accompanied by blurred vision and occasionally by nausea. Ophthalmologic examination disclosed normal vision but bilaterally elevated optic discs. (Figure 6)

Brain CT was normal. LP showed an opening pressure of 23 cm H₂O with a normal formula. Based on a provisional diagnosis of IIH, he was placed on acetazolamide 125 mg/day. Because of continued headaches, he underwent a second LP that showed an opening pressure of 27 cm H₂O. Acetazolamide was increased to 325 mg/day. When headaches did not improve, he had a third LP with an opening pressure of 38 cm H₂O, then serial LPs with an opening pressures of 48, 23, 20, and 50 cm H₂O.

Neuro-ophthalmologic examination showed normal visual function and elevated optic discs judged to be congenitally anomalous. ICP monitoring showed ICPs ranging between 2 and 15 cm H₂O. Acetazolamide was discontinued in favor a tricyclic agent. Headaches gradually dissipated and were gone within several months. Six years later he reported rare headaches that were easily treated with medication.

Summary: ICP monitoring was normal in a young boy with headache and elevated optic discs and normal visual function who had 6 LPs showing elevated opening pressures. The ICP monitoring sustained the impression that the optic disc elevation was congenitally anomalous. The headache was successfully treated with medication and 6 years later the ophthalmic findings were unchanged.

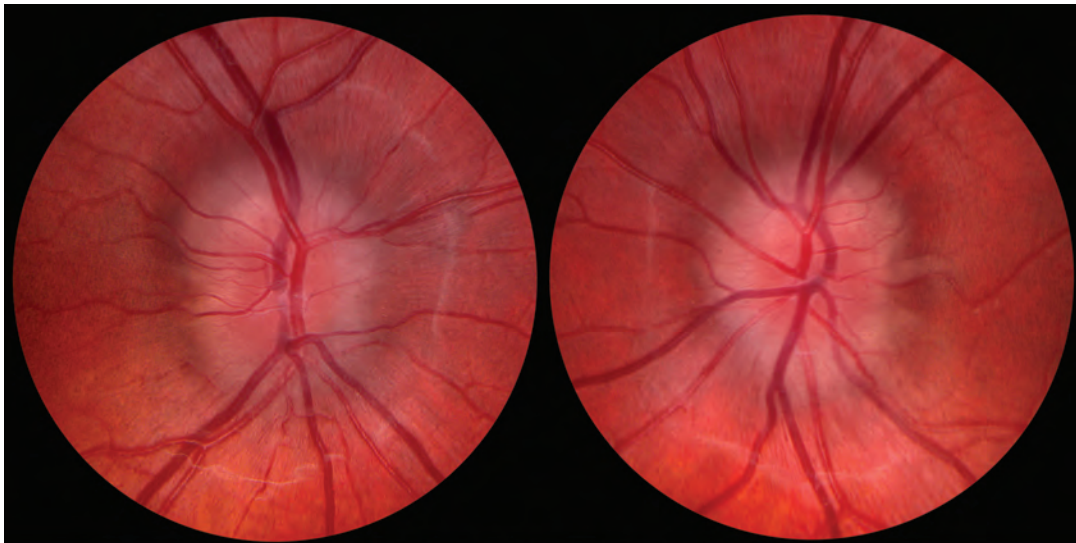


Figure 6. Case 6. Congenitally anomalous optic discs OU.

Case 7.

An 11-year-old boy complained of severe headache. Neurologic and ophthalmologic examinations and brain CT were normal, but LP showed an opening pressure of 45 cm H₂O. Five subsequent LPs had shown high opening pressures and had only transiently relieved headache. When acetazolamide treatment did not relieve headache, he underwent placement of a lumboperitoneal (LP) shunt. Neuro-ophthalmologic examination disclosed no abnormalities, including the presence of normal optic discs with spontaneous venous pulsations. ICP monitoring with the LP shunt clamped showed ICPs ranging between 5 and 15 cm H₂O. The LP shunt was removed. Headache was treated with nortriptyline. Two years later, he reported minimal headaches no longer requiring treatment.

Summary. ICP monitoring was normal in a young boy with headache but no papilledema who had undergone 6 LPs with elevated opening pressures. A LP shunt, which had been placed as a result of the high opening pressures, was removed and 2 years later, the patient had minimal headache and a normal ophthalmic exam.

Case 8.

A 25-year-old woman reported new headache and rapid loss of peripheral vision over a 1-month period. Ophthalmologic examination elsewhere had reported revealed optic disc elevation in both eyes. She was treated with maximal doses of acetazolamide and furosemide with no improvement. Brain MRI was normal. LP revealed an opening pressure of 50 cm H₂O. Because of the rapid and severe nature of vision loss, a VP shunt was placed with improvement in headache, visual fields, and optic disc swelling over the following month.

On follow-up examination 1 year later, she complained of intermittent headaches attributed to migraine. Visual acuities were 20/20 in the right eye and 20/25 in the left eye. Ophthalmoscopy revealed flat, pale optic discs in both eyes. (Figure 7) Visual fields, unchanged from prior examinations, showed mean deviations of -24 dB in the right eye and -17 dB in the left eye.

Approximately 7 years after shunt placement, she complained of increasing headaches, neck pain, and worsening vision. Visual acuity was 20/20 in both eyes. Ophthalmoscopy disclosed bilateral optic disc pallor. Visual fields were unchanged. On a shunt series, the abdominal portion of the VP shunt was disconnected. LP was not performed. ICP monitoring showed intracranial pressures ranging from 8 to 12 cm H₂O. A diagnosis of migraine was established and the VP shunt was not revised.

One year later, her headaches had improved and ophthalmic features were unchanged.

Summary: ICP monitoring was normal in a patient with a firm diagnosis of IIH who complained of worsening vision but whose visual function had not changed. Bilateral optic disc pallor precluded the use of that sign. No ICP-lowering measures were undertaken and symptoms eventually dissipated.

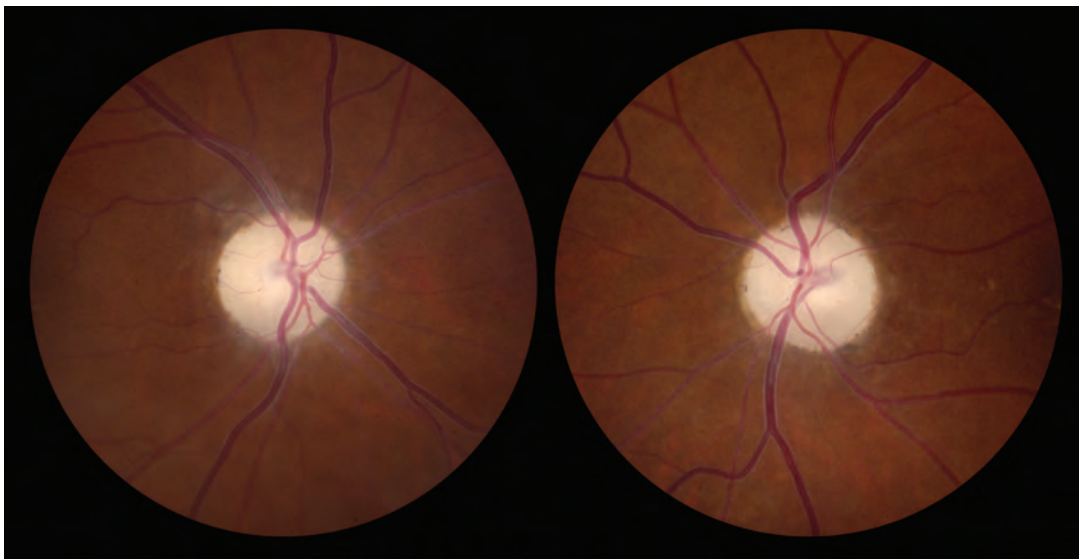


Figure 7. Case 8. Optic disc pallor OU.

Case 9.

An 8-year-old girl reported increasing headache over the past 6 months. A VP shunt had been placed at age 5 when an ophthalmologist had recorded normal visual acuities but elevated optic discs during a routine examination elsewhere. Brain MRI had been normal, but serial LPs had revealed consistently elevated opening pressures despite treatment with acetazolamide and furosemide. After VP shunt placement, she had reported that her head finally felt “normal”. Optic discs appeared unchanged.

She remained headache-free for 2 years. After falling off a playground high bar, she experienced new headache and underwent a shunt series that revealed a fracture of the cervical portion of the shunt. Shunt revision was performed. One month later, headaches returned, resulting in revision of the abdominal portion of the shunt. Headaches did not improve after surgery. Repeat LPs showed opening pressures of 22-24 cm H₂O. Additional revision of the shunt was under consideration.

Neuro-ophthalmologic examination revealed visual acuities of 20/25 in the right eye and 20/20 in the left eye. Ophthalmoscopy revealed optic disc drusen. (Figure 8) Visual fields showed multiple fixation losses but were otherwise normal.

ICP monitoring revealed pressures ranging from 2 to 17 cm H₂O during her typical headache. No further shunt revision occurred. She was started on migraine prophylaxis. One year later, she reported improvement in headache. Visual function remained normal and there was no change in the appearance of the optic discs.

Summary: ICP monitoring was normal in a young girl with optic disc drusen who complained of new headache in the setting of a previous diagnosis of IIH based on high LP opening pressures. A VP shunt had been placed years earlier. A current LP showed a borderline elevated opening pressure. The normal ICP monitoring allowed the headache to be attributed to migraine and the avoidance of further intervention.

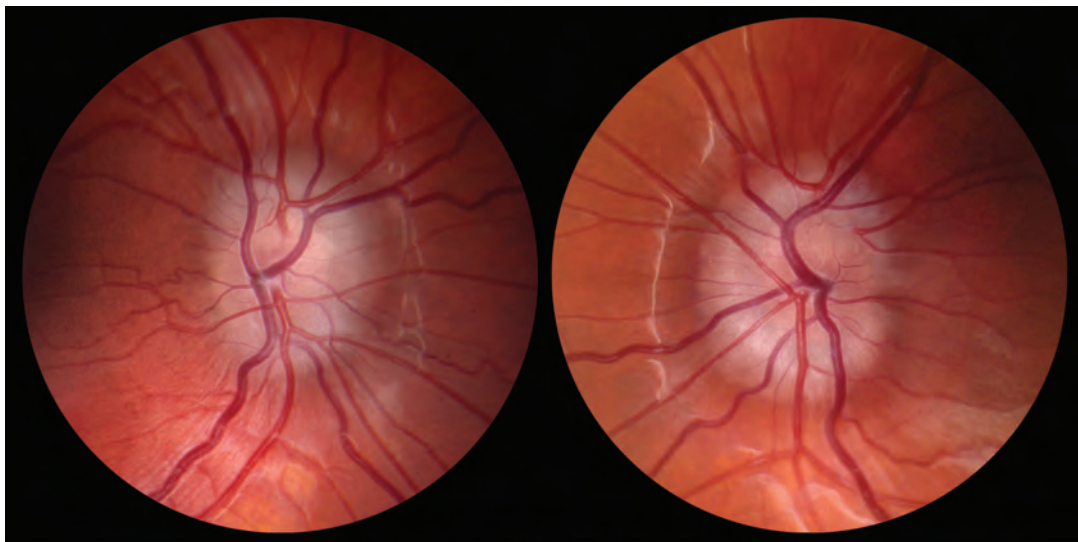


Figure 8. Case 9: Optic disc drusen OU.

Case 10.

A 49 year old woman developed transient postural obscurations of vision in her left eye. An ophthalmologist diagnosed IIH on the basis of normal brain imaging and elevated opening pressure on LP. He prescribed acetazolamide but the patient could not afford medical care or medications and was lost to follow-up. Ten years later, she suffered a mild head injury in a motor vehicle accident and a brain CT disclosed a petroclival mass.

On our neuro-ophthalmologic examination, the patient reported that vision had been failing in both eyes. Visual acuities were 20/20 in the right eye and no light perception in the left eye, there was a left afferent pupil defect, and the visual field of the right eye showed a mean deviation of -16 dB. The right optic disc displayed features of chronic edema and the left optic disc displayed pallor, findings that suggested longstanding, neglected IIH (Figure 9).

Because the petroclival mass precluded safe LP performance, she underwent ICP monitoring that showed pressures consistently above 25 cm H₂O. She underwent VP shunting and four months later, uneventful partial excision of the mass, which proved to be a meningioma.

Over 4 years of follow-up, the right optic disc edema was replaced with mild pallor, and the visual field mean deviation has remained constant.

Summary: A woman with IIH that was medically untreated because of noncompliance eventually lost all vision in one eye and partial vision in the other eye. Examination disclosed chronic optic disc edema in one eye and pallor in the other eye. LP was considered unsafe owing to the presence of a posterior fossa mass, so she underwent ICP monitoring that confirmed ongoing elevated ICP. Placement of a VP shunt led to regression of the optic disc edema and preservation of sight in the right eye.

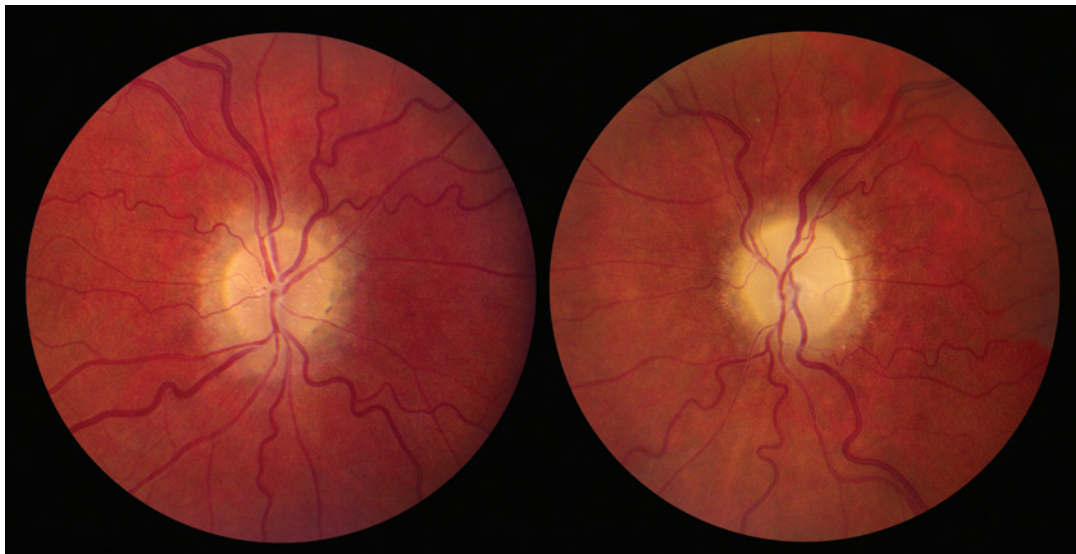


Figure 9. Case 10: Chronic optic disc edema O and pallor OS.